

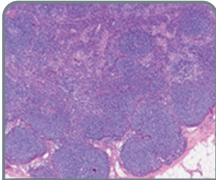
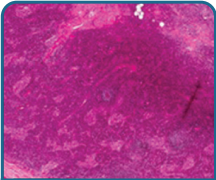
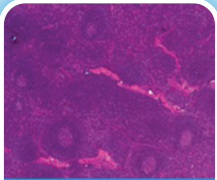
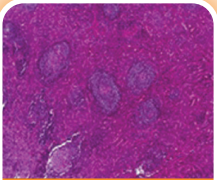
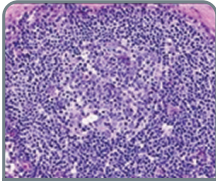
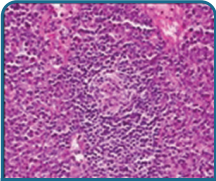
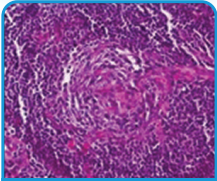
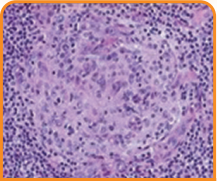
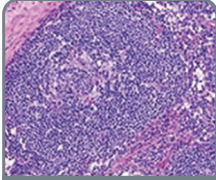
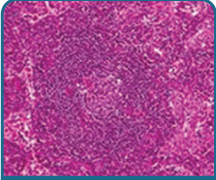
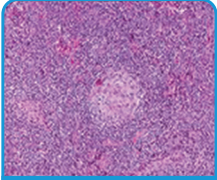
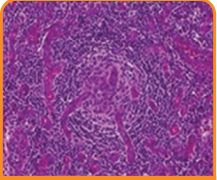
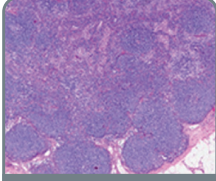
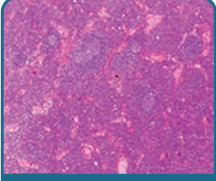

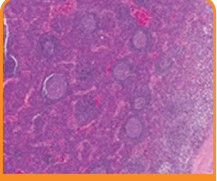
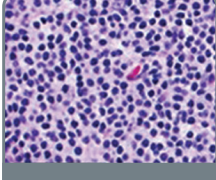
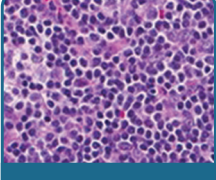
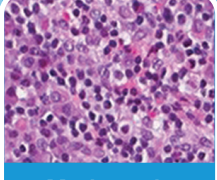
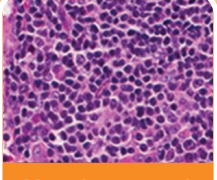
THINK iMCD

Diagnosing idiopathic multicentric Castleman disease (iMCD): Expert guidance on the assessment of excisional biopsies

Diagnosis requires lymph node morphology showing Grade 2 or 3 regressed germinal centers or plasmacytosis¹

iMCD is a rare, cytokine storm–driven disease characterized by lymphadenopathy at multiple lymph node sites¹

Five histopathological features should be graded in the diagnosis of iMCD¹:

Histopathological features	Grade			
	0	1	2	3
Regressed germinal centers (GCs)	 No regressed GCs	 Few regressed GCs	 Many regressed GCs	 Most regressed GCs
Follicular dendritic cell (FDC) prominence	 No FDC prominence	 Mild FDC prominence	 Moderate FDC prominence	 Very prominent FDCs
Vascularity	 Normal	 Mildly increased	 Moderately increased	 Very prominent
Hyperplastic germinal centers	 No hyperplastic GCs	 Few hyperplastic GCs	 Many hyperplastic GCs	 Most hyperplastic GCs
Plasmacytosis	 Normal	 Mildly increased	 Moderately increased	 Very increased ("sheet-like")

Step 1

Grading

- There are 5 histopathological features that should be graded when assessing excisional biopsies for iMCD¹
- Patients need a Grade 2 or 3 for regressed germinal centers or plasmacytosis, as well as other features consistent with the iMCD histologic spectrum¹

Step 2

Exclusionary requirements

- Once the presence of histopathological features has been confirmed, a diagnosis of iMCD requires the exclusion of diseases that can have similar presentations¹
- Some diseases can be excluded by pathology, and others must be excluded by the treating physician¹

Step 3

Histopathological subtyping

- The final step in the process is to assess which histopathological subtype applies
- There are three established histopathological subtypes of iMCD¹:
 - Hypervascular (formerly hyaline-vascular)
 - Mixed
 - Plasmacytic
- The clinical relevance of these subtypes remains somewhat unknown, but in certain scenarios, the confirmation of subtype may help drive treatment decisions¹



Clinical collaboration with the treating physician facilitates appropriate diagnosis and management¹



Visit ThinkiMCD.us
to learn more

Contact your Recordati Rare Diseases
Account Manager today for more information